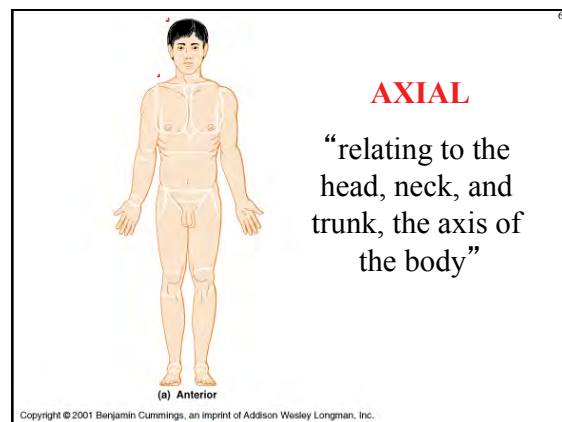
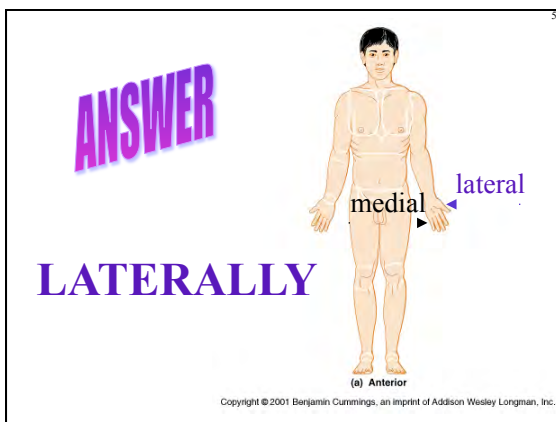
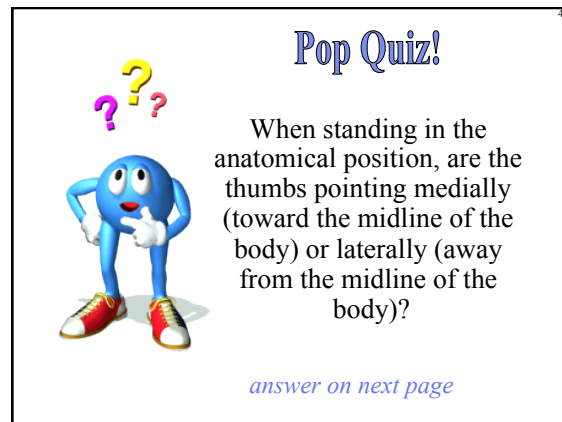
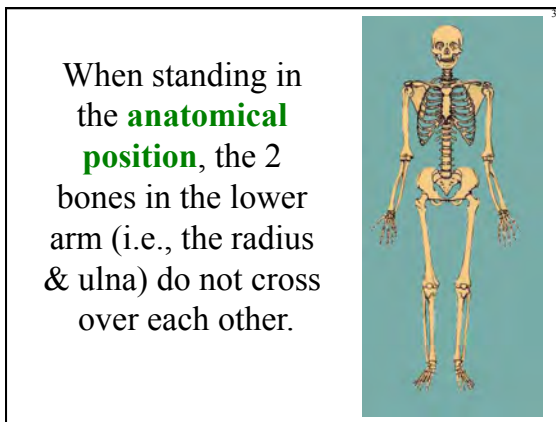
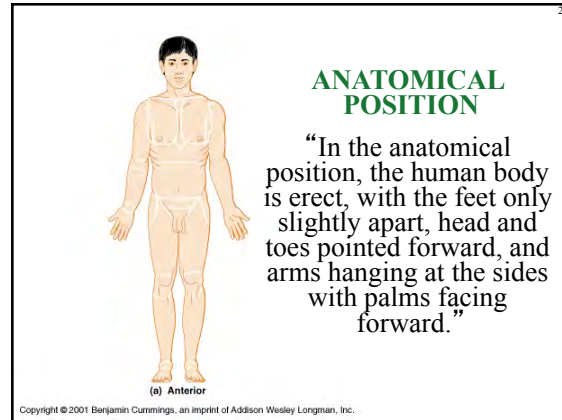
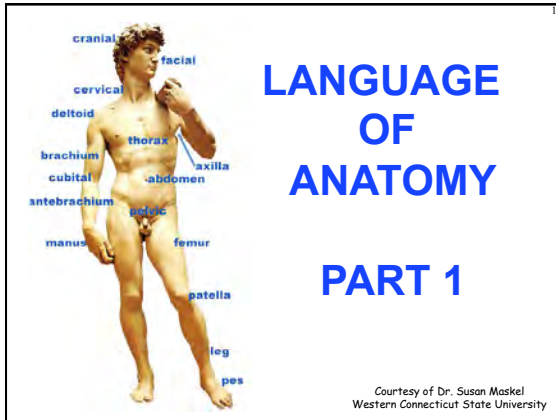
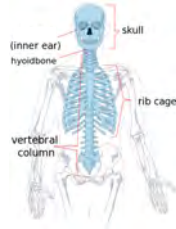

THE LANGUAGE of ANATOMY PART 01



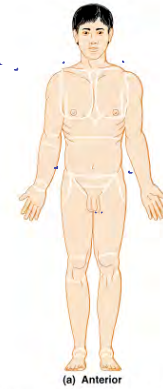THE LANGUAGE of ANATOMY PART 01

The **axial** skeleton consists of the skull, the ossicles, the hyoid bone, the vertebral column, the ribs, and the sternum.



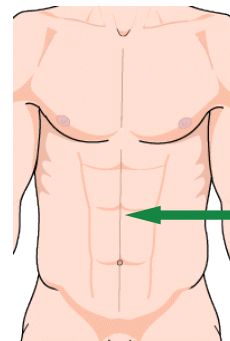
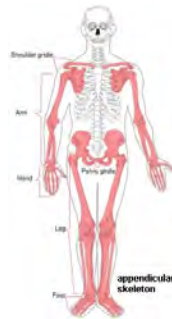APPENDICULAR

“relating to limbs and their attachments to the axis”



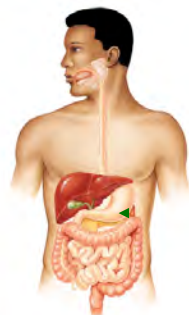Copyright © 2001 Benjamin Cummings, an imprint of Addison Wesley Longman, Inc.

The **appendicular** skeleton consists of the arms, the bones that attach the arms to the body (i.e., the clavicles & scapulae), the legs, and the bones that attach the legs to the body (i.e., the hipbones).



ABDOMINAL

“pertaining to the anterior body trunk inferior to the ribs”



The stomach is located in the **abdominal** cavity.

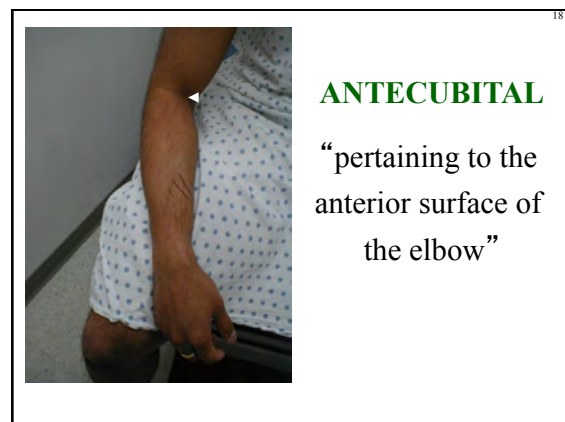
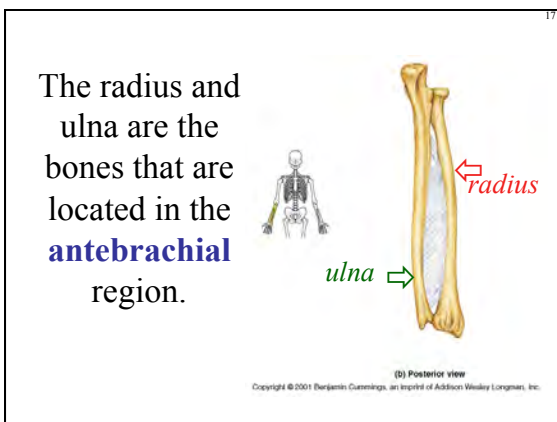
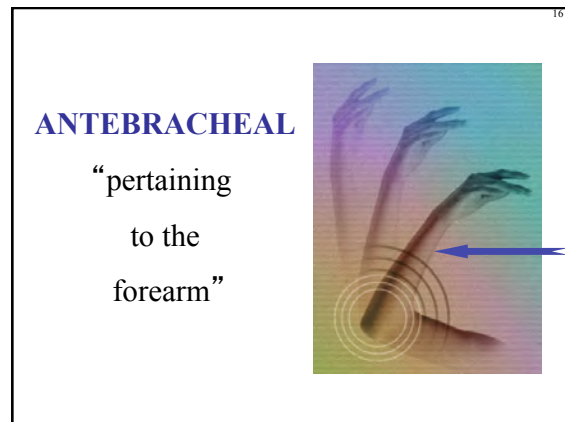
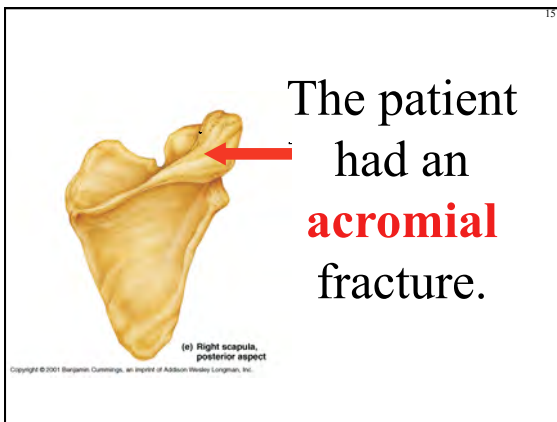
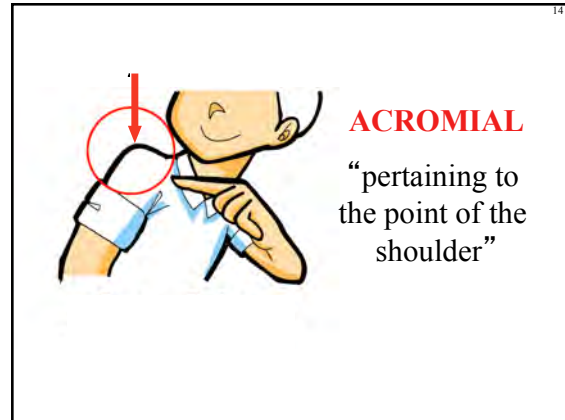
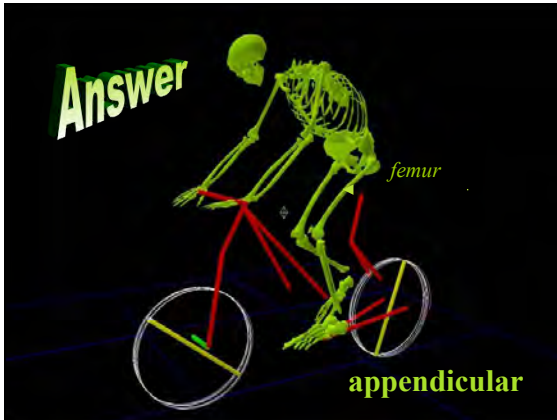

Pop Quiz!

Is the femur (i.e., the thigh bone) in the axial, appendicular, or abdominal region of the body?

answer on next page

THE LANGUAGE of ANATOMY PART 01



THE LANGUAGE of ANATOMY PART 01


19



Pulse can be taken using the brachial artery. To find this artery, press firmly on the skin at or just above the **antecubital** region.

20

Pop Quiz!



What do you call the region of the body between the elbow and the wrist?

answer on next page


21

ANSWER



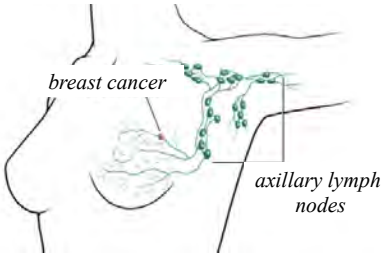
ANTEBRACHIAL REGION

22



AXILLARY
“pertaining to the armpit”

23




breast cancer
axillary lymph nodes

Axillary lymph nodes are sometimes removed during breast cancer surgery.

24

BRACHIAL


“pertaining to the arm”



Note: refers to upper arm; between shoulder & elbow

THE LANGUAGE of ANATOMY PART 01


25



When taking a patient's blood pressure, the cuff of the sphygmomanometer is placed around the **brachium** & **brachial** artery.

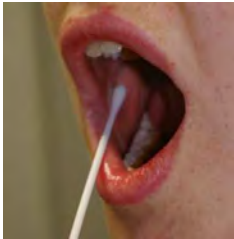
26

BUCCAL
"pertaining to the cheek"




27

In an A&P lab, you are going to prepare a **buccal** smear (i.e., a wetmount of cells from the inside of your cheek).



28

Pop Quiz!




What is the common name of the body part where axillary lymph nodes are found?

answer on next page

29


Answer:



armpit


30

CARPAL
"pertaining to the wrist"



**THE LANGUAGE of ANATOMY
PART 01**

31




Median nerve is compressed at the wrist, resulting in numbness or pain


Carpal Tunnel Syndrome occurs when the median nerve is squeezed.

32

CERVICAL
“pertaining to the neck region”

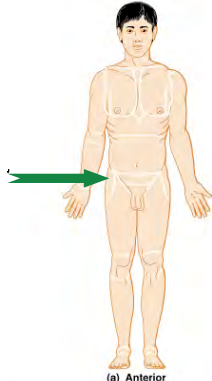


33



The mouse was sacrificed using **cervical** dislocation.

34




COXAL
“pertaining to the hip”

(a) Anterior

Copyright © 2001 Benjamin Cummings, an imprint of Addison Wesley Longman, Inc.


35



The elderly lady who lives next door fell down and broke her left **coxal** bone.

36

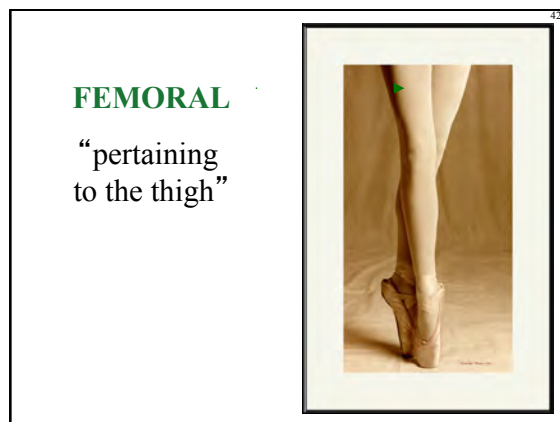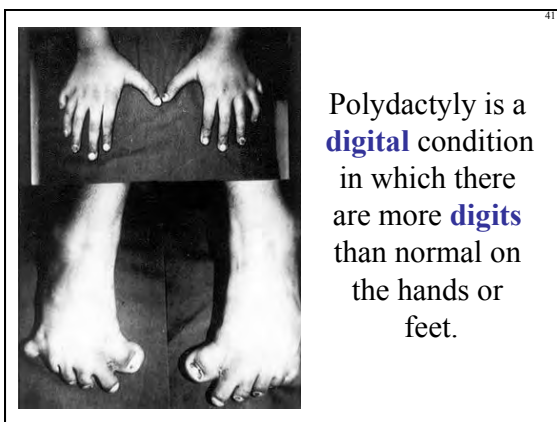
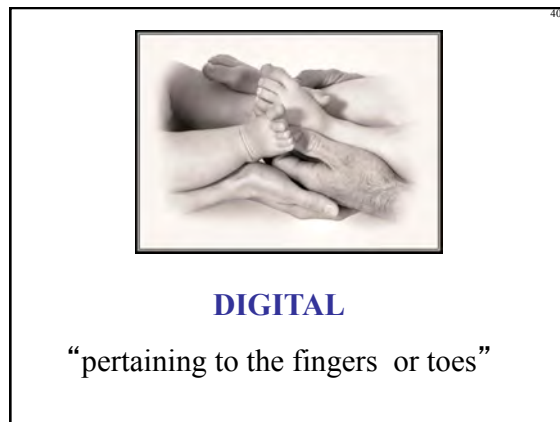
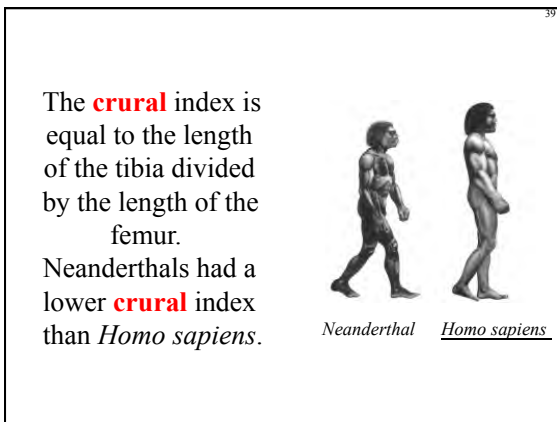
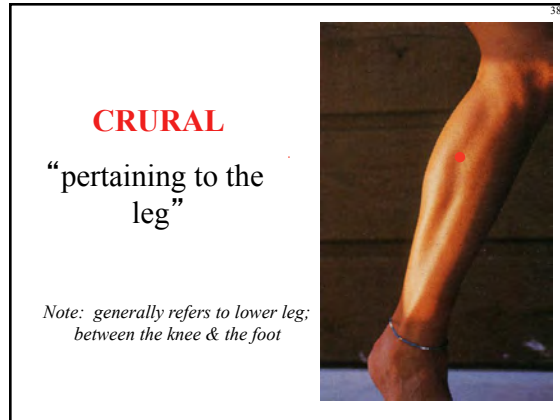Pop Quiz!



If a patient needs to wear a cervical collar, what is the common name of the part of the body that the collar is worn on?

answer on next page

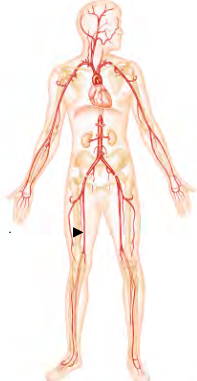
THE LANGUAGE of ANATOMY PART 01



THE LANGUAGE of ANATOMY PART 01

43


The **femoral** artery is located in the thigh region.



(b)
Copyright © 2001 Benjamin Cummings, an imprint of Addison Wesley Longman, Inc.

44

Pop Quiz!

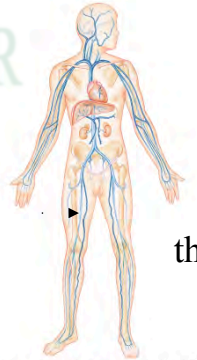


What is the common name of the part of the body in which you would expect to find the femoral vein?

answer on next page

45

ANSWER



the thigh

(b)
Copyright © 2001 Benjamin Cummings, an imprint of Addison Wesley Longman, Inc.

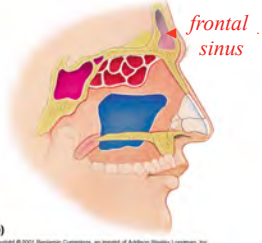
46

FRONTAL

“pertaining to the forehead”



47



frontal sinus

(b)
Copyright © 2001 Benjamin Cummings, an imprint of Addison Wesley Longman, Inc.

The **frontal** sinus is located in the **frontal** bone (which is the bone that makes up the forehead).

48


HALLUX

“pertaining to the great toe”

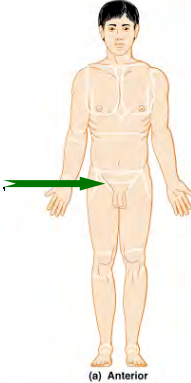


THE LANGUAGE of ANATOMY
PART 01

Orangutans use their **hallux** the same way people use their pollex (i.e., thumb).



49



INGUINAL
“pertaining to the groin”

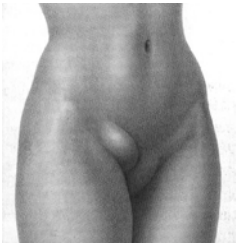
Note: the groin is the area where the legs connect to the trunk of the body

(a) Anterior

Copyright © 2001 Benjamin Cummings, an imprint of Addison Wesley Longman, Inc.


50

This patient has an **inguinal** hernia.



51

Pop Quiz!



What is the scientific name for the big toe?

answer on next page

52




Answer

hallux

53

MAMMARY
“pertaining to the breast”



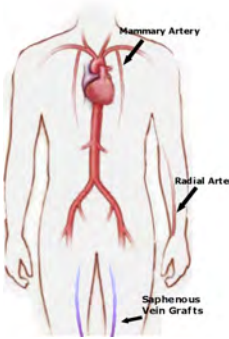
(a) Anterior

Copyright © 2001 Benjamin Cummings, an imprint of Addison Wesley Longman, Inc.

54


**THE LANGUAGE of ANATOMY
PART 01**

55




The **mammary** arteries are also called the internal thoracic arteries. These blood vessels deliver blood to the majority of the anterior wall of the thorax.

56



MENTAL
“pertaining to the chin”

57




The **mental** foraminae (foraminae = holes) are found in the mandible (i.e., the lower jaw bone).

(a)
Copyright © 2001 Benjamin Cummings, an imprint of Addison Wesley Longman, Inc.


58

NASAL
“pertaining to the nose”




59

Vibrissae (nasal hairs) are found in the nasal cavity.



60

Pop Quiz!



What is the common name of the area of the body where you would expect to find the muscle named the mentalis?


answer on next page

THE LANGUAGE of ANATOMY
PART 01

61


answer

CHIN



Copyright © 2001 Benjamin Cummings, an imprint of Addison Wesley Longman, Inc.

62




ORAL

“pertaining to the mouth”

(b)
Copyright © 2001 Benjamin Cummings, an imprint of Addison Wesley Longman, Inc.

63


Mr. Smith is going to an **oral** surgeon to have his tooth pulled.



64

ORBITAL


“pertaining to bony eye socket (orbit)”




(a)
Copyright © 2001 Benjamin Cummings, an imprint of Addison Wesley Longman, Inc.

65

The lacrimal (tear) glands and the muscles that are responsible for eye movement are found in the **orbital** region.



66

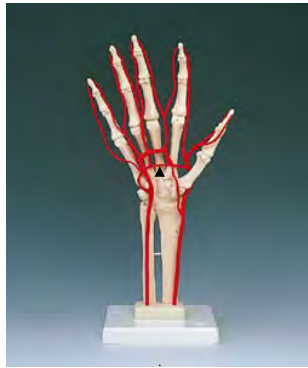

PALMAR

“pertaining to the palm of the hand”

THE LANGUAGE of ANATOMY
PART 01

The deep **palmar** arch is an artery found in the **palm** of the hand.



Pop Quiz!



Another name for the buccal cavity is the **_?_** cavity.

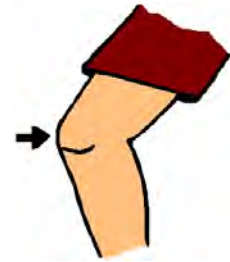- A. oral
- B. nasal
- C. orbital

answer on next page

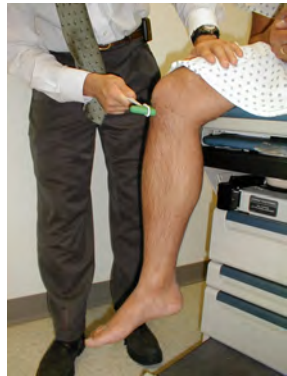Answer
A. oral

PATELLAR

“pertaining to anterior knee (kneecap) region”

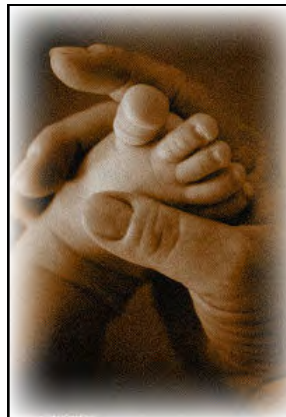

The doctor tested the patient's **patellar** reflex by tapping a rubber mallet on his **patellar** tendon.



PEDAL

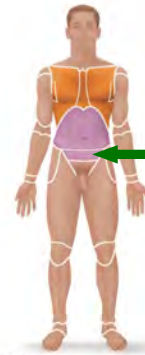“pertaining to the foot”



THE LANGUAGE of ANATOMY PART 01



Humans are **bipedal** organisms.
This means that they walk on two feet.



PELVIC

“pertaining to the
pelvis region”

(a)

Copyright © 2010 Pearson Education, Inc.



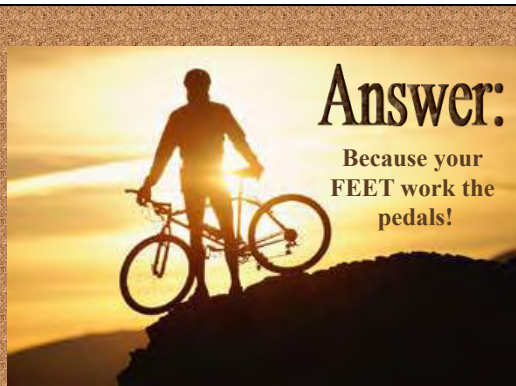
In the 1950' s and
1960' s, Elvis
Presley stunned the
public gyrating his
pelvic area on
television.



Pop Quiz!

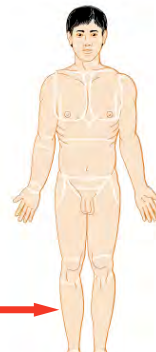Why do you suppose the
pedals on a bicycle are
called pedals?

answer on next page



Answer:

Because your
FEET work the
pedals!



FIBULAR or PERONEAL

“pertaining to the
side of the leg”

(a) Anterior

Copyright © 2001 Benjamin Cummings, an imprint of Addison Wesley Longman, Inc.

**THE LANGUAGE of ANATOMY
PART 01**

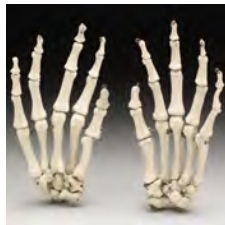Peroneal, perineal, and peritoneal refer to different regions of the body. Don't get them mixed up!

POLLEX

"pertaining to the thumb"

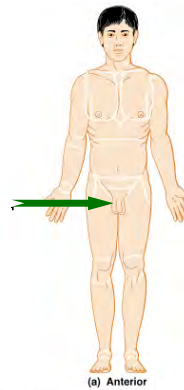


All fingers have 3 phalanges (finger bones) except the **pollices**; each **pollex** has only 2 phalanges.



PUBIC

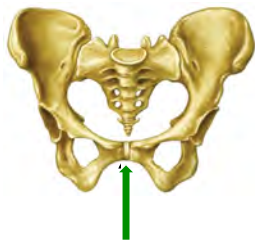
"pertaining to the genital region"



(a) Anterior

Copyright © 2001 Benjamin Cummings, an imprint of Addison Wesley Longman, Inc.

The **pubic** symphysis is the joint where the two hipbones meet anteriorly (i.e., in the front).



Pop Quiz!



There are 2 bones in the lower leg - the tibia & the fibula. Which one do you think is more laterally located?

answer on next page

THE LANGUAGE of ANATOMY PART 01

85

Answer: The **FIBULA** is more lateral; it is in the fibular or peroneal area

LATERAL side of leg

MEDIAL side of leg

Femur

Fibula

Tibia

86

STERNAL

“pertaining to the region of the breastbone”

(a) Anterior

Copyright © 2001 Benjamin Cummings, an imprint of Addison Wesley Longman, Inc.

87

In lab next semester, you will open the chest cavity of a dead cat by cutting to the right or the left of the **midsternal** line.

88

TARSAL

“pertaining to the ankle”

89

A person's ankle is made up of 7 tarsal bones.

Tarsal bones

Metatarsal bone

Phalanges

© ADAM

90

THORACIC

“pertaining to the chest”

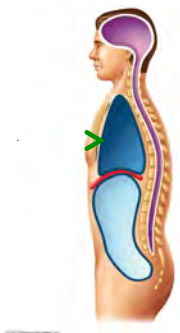
(a) Anterior

Copyright © 2001 Benjamin Cummings, an imprint of Addison Wesley Longman, Inc.

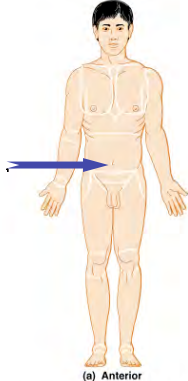
THE LANGUAGE of ANATOMY PART 01

91

The pleural cavities (which house the lungs) and the pericardial cavity (which houses the heart) are all found within the **thoracic** cavity.



92




UMBILICAL
“pertaining to the navel”

(a) Anterior

Copyright © 2001 Benjamin Cummings, an imprint of Addison Wesley Longman, Inc.


93

After the baby was born, the proud father had the honor of cutting the **umbilical** cord.



94

Pop Quiz!



Your largest ankle bone is your heal bone or calcaneus. This bone is one of 7 bones called **??** found in each foot.

answer on next page

95


Answer: **TARSALS**



(c) Lateral view

Copyright © 2001 Benjamin Cummings, an imprint of Addison Wesley Longman, Inc.

96



end of
Part 1 of
The
Language
of
Anatomy