


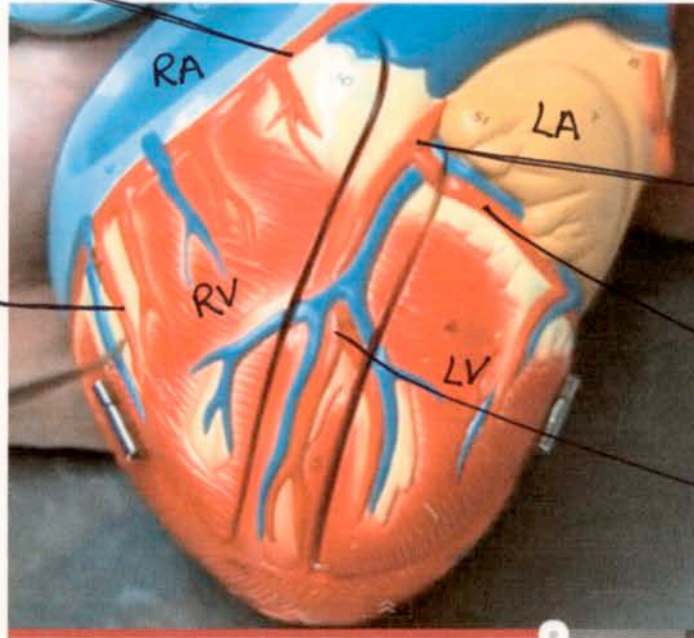
HEART MODEL in the A&P LAB



- A - Right Brachiocephalic Vein
- B - Left Brachiocephalic Vein
- C - Right Brachiocephalic Artery
- D - Left Common Carotid Artery
- E - Left Subclavian Artery

Anterior

Right Coronary Artery



Marginal Artery

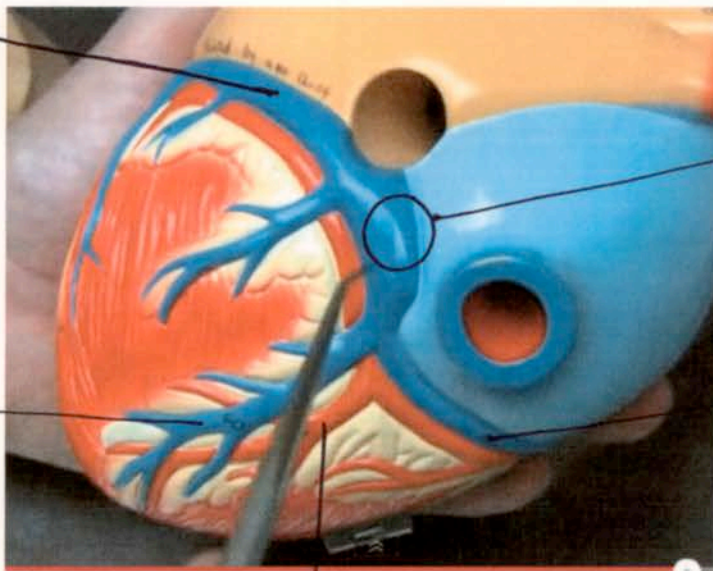
Left Coronary Artery

Circumflex Artery

Anterior Interventricular Artery

Posterior

Great Cardiac Vein



Middle Cardiac Vein

Coronary Sinus

Small Cardiac Vein

Posterior Interventricular Artery